



# Posterior Scleritis with Optic Nerve Edema Presenting in a Case of Atypical Cogan's Syndrome

**Layla Mazdeyasnan<sup>1</sup>, Zian Shabbir<sup>1</sup>, Gregory Lewis, MD<sup>2</sup>**

<sup>1</sup>California Health Sciences University College of Osteopathic Medicine-Clovis, California

<sup>2</sup>Kaiser Permanente-Fresno, California

DOI: 10.62856/djcro.v7.47

\*Corresponding Author

**Layla Mazdeyasnan**

College of Osteopathic Medicine-Clovis

California Health Sciences University

24607 Stonegate Drive

West Hills, CA 91304

E-mail: [mazdeyasnan2654@chsu.edu](mailto:mazdeyasnan2654@chsu.edu)

## Introduction

Cogan's syndrome is a rare, systemic autoimmune disorder characterized by ocular and auditory manifestations.<sup>1</sup> The classic form of Cogan's syndrome typically involves non-syphilitic interstitial keratitis and sensorineural hearing loss with vestibular symptoms resembling Ménière's disease.<sup>2</sup> However, the atypical presentation of Cogan's syndrome can involve a broader spectrum of ocular inflammation and auditory disturbances. Atypical Cogan's syndrome often lacks the hallmark features of interstitial keratitis and has a time interval of more than two years between the ocular and auditory manifestations.<sup>2</sup> While the disease remains idiopathic, its autoimmune etiology has been widely recognized. Treatment strategies focus on aggressive immunosuppression to prevent irreversible damage.<sup>3</sup> In this case report, we describe the clinical course of a 37-year-old female who presented with progressive ocular and auditory symptoms, ultimately leading to a diagnosis of atypical Cogan's syndrome. This case underscores the complexity of diagnosing Cogan's syndrome and highlights the importance of early intervention and multidisciplinary management in preventing long-term complications.

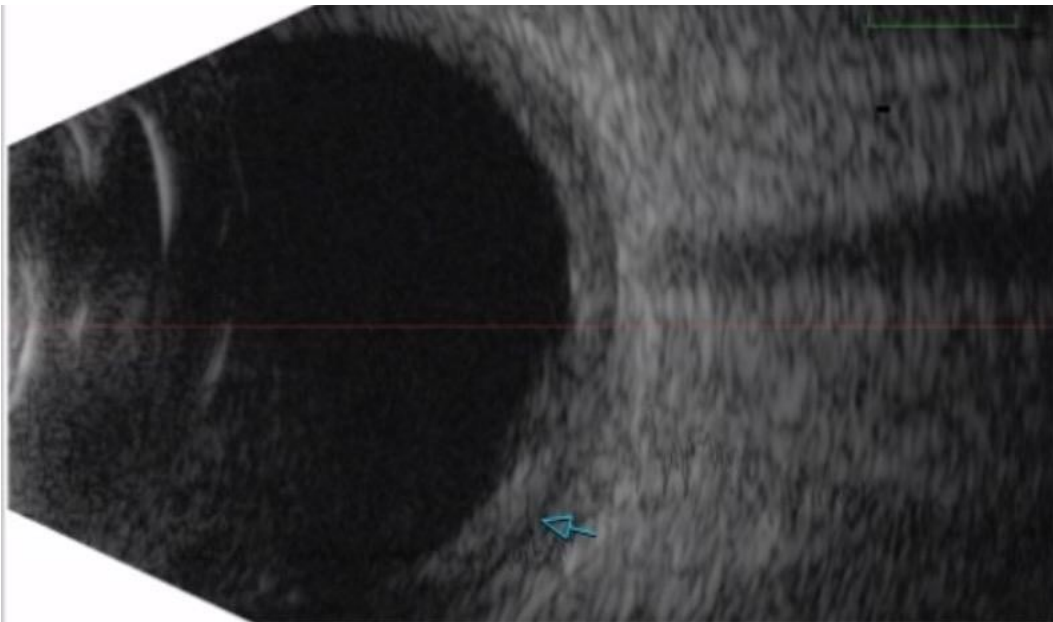
## Case Report

A 37-year-old female with a history of a stable cerebellar peduncle, previously evaluated and found to have no significant changes, presented to her primary care physician with worsening vision in both eyes. She described experiencing headaches, photophobia, and blurred vision, mainly in her right eye. A brain MRI without intravenous contrast performed was read as normal. Eleven days later, at her initial ophthalmology visit, visual acuity measured 20/150 in the right eye and 20/30 in the left eye. She had bilateral eye pain, and both eyes had

2+ cell in the anterior chamber with posterior synechiae. There were no posterior segment findings at the time of the initial presentation. Topical steroids were started for the iritis. Four days later, bilateral choroidal folds and optic nerve edema were present. A diagnosis of bilateral posterior scleritis and optic disc edema was made, with papilledema suspected. A lumbar puncture with opening pressure was not performed to confirm the presence of papilledema.

Extensive laboratory testing was conducted to rule out other autoimmune and infectious etiologies.<sup>4</sup> An interferon-gamma release assay (for tuberculosis) and syphilis serology were negative. Antibodies to cardiolipin, antinuclear antibody (ANA), extractable nuclear antigens (ENA), and antineutrophil cytoplasmic antibodies (ANCA) were all negative. Additionally, angiotensin-converting enzyme (ACE), rheumatoid factor (RF), complete blood count (CBC), and metabolic profile were all within normal limits. These findings helped rule out conditions such as rheumatoid arthritis, granulomatosis with polyangiitis, and systemic lupus erythematosus. The patient was started on naproxen 500 mg twice daily and oral prednisone 60 mg daily, tapered over 12 days.

By the fifth day of oral prednisone, the patient's symptoms and choroidal folds had resolved. However, five days after completing the prednisone taper, she presented with new-onset bilateral hearing loss and tinnitus. Audiological testing revealed bilateral sensorineural hearing loss but was considered inconclusive due to poor test reliability. Anti-cochlear antibodies (heat shock protein 70, Hsp70) were ordered and four days later returned positive, pointing to an autoimmune etiology for the hearing loss.<sup>5</sup> Atypical Cogan's syndrome was diagnosed based on the presence of posterior scleritis and sensorineural hearing loss. At this time, the patient had a recurrence of posterior scleritis and optic nerve edema, with visual acuity of 20/400 in the right eye and 20/70 in the left. B-scan ultrasound revealed scleral thickening with sub-Tenon's fluid (the T sign), as demonstrated in the Figure. In response, the patient was started on a second course of oral prednisone, with a dose increase to 80mg followed by a taper over a six-week period.



**Figure.** B-scan ultrasound picture of the left eye showing scleral thickening with sub-Tenon's fluid (blue arrow).

Five days later, visual acuity was 20/25 in both eyes, and the posterior scleritis had resolved entirely, allowing for the discontinuation of naproxen. At the same time, the optic nerve edema had not yet subsided. An audiological test was abnormal bilaterally, but results were still unreliable due to the persistent tinnitus. One

month later, at follow-up with her ophthalmologist, the patient was asymptomatic with a visual acuity of 20/25 in each eye. A fundus exam showed that both optic nerves had returned to normal appearance. Also, at that time, the patient reported complete resolution of tinnitus, and follow-up audiological testing showed good reliability that all previously abnormal thresholds had normalized. While the oral prednisone was still being tapered, a rheumatologist placed the patient on methotrexate at a dose of 15mg orally once a week. Six months following the onset of her symptoms, the patient was still being maintained on methotrexate 15 mg weekly. Visual acuity was 20/20 in both eyes, her hearing remained normal bilaterally with no recurrence of tinnitus, and there were no signs of active inflammation.

## Discussion

This case highlights the challenges in diagnosing atypical Cogan's syndrome in a timely fashion to prevent permanent hearing loss. Cogan's syndrome manifests with a broad spectrum of clinical features. Classic findings of interstitial keratitis, audio-vestibular dysfunction, and a two-week onset characterize typical cases.<sup>4</sup> In contrast, atypical cases involve more diverse ocular and systemic manifestations with a longer progression.<sup>1</sup> In addition, our patient presented with progressive ocular and auditory symptoms, including bilateral uveitis, optic nerve edema, posterior scleritis, and sensorineural hearing loss. These findings differ from the classic presentation of typical Cogan's syndrome. This case emphasizes the importance of considering atypical Cogan's syndrome presentations, which may complicate the diagnosis and management, as this is a diagnosis of exclusion. For example, although posterior scleritis would be very uncommon in ocular sarcoidosis, it is acknowledged that normal ACE levels and a chest X-ray alone may not fully exclude sarcoidosis. Further investigation, including a chest CT, lumbar puncture (to rule out papilledema from elevated intracranial pressure), and cerebrospinal fluid analysis were not performed but could have provided additional diagnostic clarity.

Although anti-Hsp70 is more commonly associated with typical Cogan's syndrome than atypical, the positive test, in this case, was still valuable in highlighting the need for aggressive treatment with steroids and immunosuppressive therapies to protect the patient's hearing.<sup>5</sup> Initially, our patient responded well to oral prednisone, but her symptoms progressed and recurred after tapering. This indicated a more severe and refractory disease course, consistent with atypical Cogan's syndrome. Tapering the steroids may have led to a resurgence of inflammation, as the underlying immune dysregulation in atypical Cogan's syndrome may not have been fully controlled by steroids alone. This prompted further investigation and a shift to more intensive treatment by initiating immunosuppressive therapy.

Given the increase and relapse of symptoms, the management of Cogan's syndrome remains challenging, mainly when the disease presents atypically or is refractory to initial steroid therapy. While steroids are often first-line treatment for typical Cogan's syndrome, their efficacy may be limited in patients with atypical forms. This underscores the need for immunosuppressive agents, such as methotrexate, to control inflammation.

This case contributes to the current literature on atypical Cogan's syndrome by emphasizing the diagnostic challenges, unique ocular manifestations, and the need for aggressive treatment to prevent hearing loss. Our findings highlight the importance of early intervention and long-term management in preventing permanent complications and improving patient outcomes.

## Conclusion

In managing atypical Cogan's syndrome, continuous monitoring and adjustment of treatment across multiple specialties, including primary care, ophthalmology, otolaryngology, and rheumatology, optimizes the outcome.

Treatment of Cogan's syndrome involves corticosteroids and other immunosuppressive agents to control inflammation and decrease the risk of irreversible organ damage.<sup>3</sup> Diagnosis is based on exclusion, and early identification of clinical symptoms is critical.

## References

1. Yaginuma A, Sakai T, Kohno H, et al. A Case of Atypical Cogan's Syndrome with Posterior Scleritis and Uveitis. *Jpn J Ophthalmol*. 2009 Nov;53(6):659-661.
2. Espinoza GM, Wheeler J, Temprano KK, et al. Cogan's Syndrome: Clinical Presentations and Update on Treatment. *Curr Allergy Asthma Rep*. 2020 Jun 16;20(9):46.
3. Gonçalves RM, Curi AL, Campos WR, et al. Posterior Scleritis in Cogan's Syndrome. *Ocul Immunol Inflamm*. 2004 Jun;12(2):149-52.
4. Grasland A, Pouchot J, Hachulla E, et al; Study Group for Cogan's Syndrome. Typical and Atypical Cogan's Syndrome: 32 Cases and Review of the Literature. *Rheumatology (Oxford)*. 2004 Aug;43(8):1007-15.
5. Bonaguri C, Orsoni J, Russo A, et al. Cogan's Syndrome: Anti-Hsp70 Antibodies Are a Serological Marker in the Typical Form. *Isr Med Assoc J*. 2014 May;16(5):285-8. PMID: 24979832.

## Statement of Ethics

This case report adheres to patient confidentiality and ethical principles in accordance with the guidelines of the Declaration of Helsinki and relevant local regulations. A written informed consent was obtained from the patient's parents authorizing publication of this medical case and accompanying images.

## Conflict of Interest Statement

The authors declare no conflicts of interest related to this topic.

## Funding

This work received no funding or grant support.

## Authorship

We attest that all authors contributed significantly to the creation of this manuscript, each having fulfilled the criteria as established by the ICMJE.