



Tolosa Hunt Syndrome: An Atypical Presentation of a Rare Condition

Jason Zehden MD¹, Basil Mathews MD², Maja Kostic MD PhD^{1*}

¹Department of Ophthalmology, University of North Carolina, Chapel Hill, NC, USA

²Duke Eye Center, Duke University, Durham, NC, USA

DOI: <https://doi.org/10.62856/djcro.v1i1.14>

*Corresponding author:

Maja Kostic, MD PhD

Kittner Eye Center at University of North Carolina

2226 Nelson Highway

Chapel Hill, NC, USA

E-mail: maja_kostic@med.unc.edu

Introduction

Tolosa-Hunt Syndrome is a rare disorder with one to two cases per one million occurring each year worldwide.¹ The first case was described by Dr. Eduardo Tolosa in 1954.² A few years later, Hunt et al. reported similar cases and demonstrated improvement with corticosteroid treatment in 1961.³ It was then in 1966 that it was first referred to as Tolosa-Hunt Syndrome.⁴ THS can occur at any age¹ and there is no predominance for males or females.^{1,5} THS is characterized by a severe, unilateral peri-orbital or hemi-cranial pain, often mimicked as headaches, associated with ophthalmoplegia.⁵ THS is an idiopathic disorder caused by non-specific granulomatous inflammation in the area of the cavernous sinus, superior orbital fissure, or orbit.^{1,5,6} It usually has a relapsing-remitting course with attacks recurring every few months or years and it is rapidly responsive to systemic corticosteroid treatment.⁵ The oculomotor, trochlear, and abducens nerves are most commonly affected in THS leading to the ophthalmoplegia.⁵ The ophthalmic branch of the trigeminal nerve is occasionally affected.⁵ Pupillary abnormalities may occur due to involvement of sympathetic and parasympathetic nerves.⁵ Even more rarely, inflammation can involve the orbital apex resulting in optic nerve damage.^{5,7} We report a case of THS with complete ophthalmoplegia, involving the optic nerve and orbital apex.

Case Report

A 59-year-old male with a history of hypertension, chronic headache, gout, and a meningioma presented to the emergency department, after leaving against medical advice from an outside hospital, with vision loss in the left eye after acute worsening of a chronic headache. He reported that the vision loss began two weeks prior and that he was now only able to visualize shadows. Additionally, one week prior, he developed ophthalmoplegia of his left eye with associated diplopia. He reported 30 pounds of unintentional weight loss over the past 12 months, decreased appetite due to nausea, and recent blood in his stool and urine. His only long-term medication was ibuprofen 600 mg every four hours for headache relief. He lived with his wife, smoked one pack of cigarettes daily, and occasionally drank beer. He had no ocular past medical history or known family history.

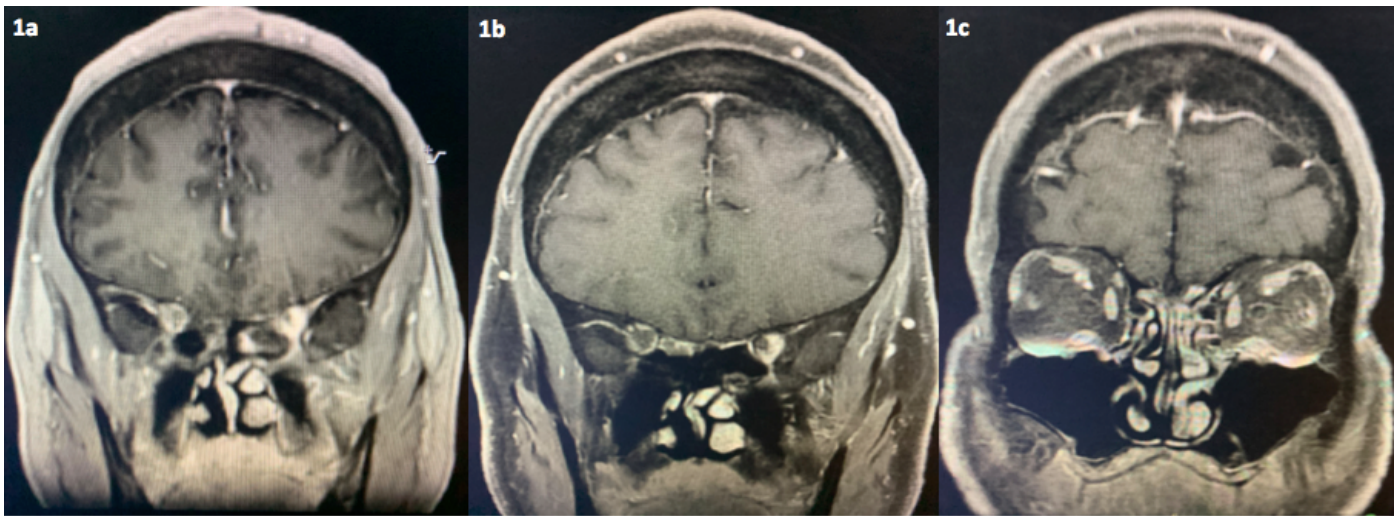


Figure 1A-B.

Prior to presentation, he was evaluated at an outside institution with a similar history as detailed above. During that hospitalization, a computed tomography angiography (CTA) of his head and neck was unremarkable. A lumbar puncture (LP) was negative for infection. Another LP was performed for flow cytometry to rule out a malignancy, but the result was pending. A CT of the chest, abdomen, and pelvis was unremarkable. MRI of the brain and orbits demonstrated an abnormal left orbit with proptosis and intraconal inflammatory change (Figure 1). There was abnormal enhancement of the left orbital apex and adjacent lateral aspect of the left sphenoid sinus (Figure 1). The patient was negative for COVID-19. A complete blood count, basic metabolic panel, liver function tests, and C-reactive protein (CRP) were within normal limits. Erythrocyte sedimentation rate (ESR) was elevated at 92 mm/hour. ACE, PSA, TSH, and T4 were all normal, HIV testing was negative, and RPR was non-reactive. Intravenous (IV) methylprednisolone was planned for presumed Tolosa-Hunt Syndrome pending an orbital biopsy to rule out a malignancy or fungal infection.

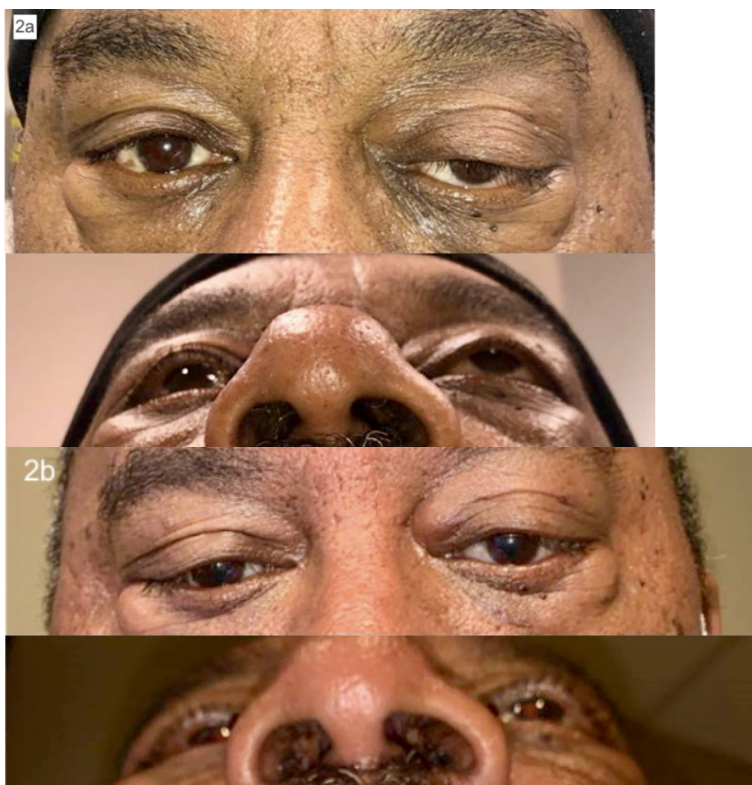

Figure 2A and 2B.

On our examination, the patient's visual acuity (VA) was 20/20 in the right eye and count fingers at three feet in the left eye. Intraocular pressure (IOP) was 19 mmHg in both eyes. Both pupils were 1.5 mm, but the left eye had a relative afferent pupillary defect. Color vision with Ishihara plates was 12/12 in the right eye and 0/12 in the left eye. A complete dilated ophthalmic examination as well as visual field testing were normal in the right eye. There was complete ophthalmoplegia (-4) and partial outer superior temporal and superior nasal deficiencies on visual field testing in the left eye. External examination revealed proptosis with upper lid ptosis of the left eye (Figure 2A). There was grade 2 disc edema per Frisen scale in the left eye. This image was taken via iPhone and was then modified to be upright and inverted (Figure 3A).

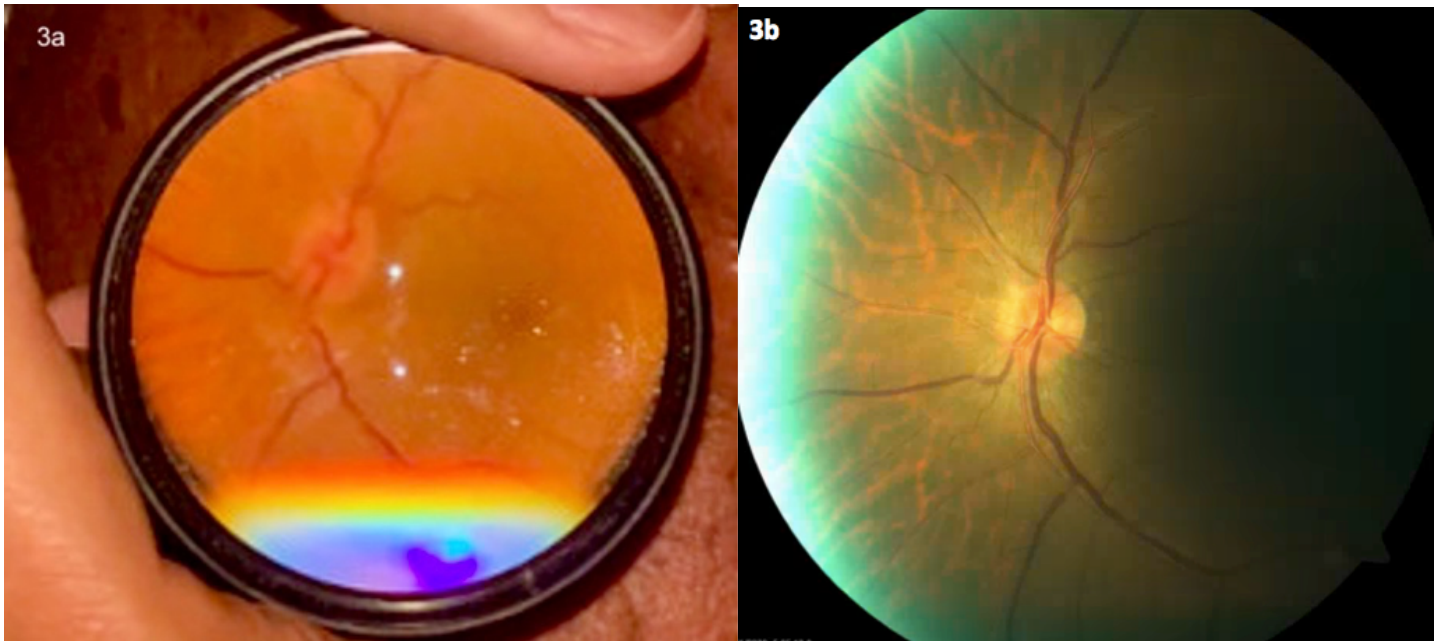


Figure 3A and 3B.

To lessen the optic disc edema, intravenous methylprednisolone 1000 mg for five days was administered after ensuring that the LP for flow cytometry had been collected to rule out malignancy; low suspicion for fungal infection, especially Mucormycoses, was noted after a negative endoscopic view of the sinuses by the otorhinolaryngology consultants. Repeat testing of PSA and RPR were normal and nonreactive, respectively. IgG4 was normal at 46.9 mg/dL. ANA, ANCA, and Quantiferon Gold testing were all normal. Visual acuity and extraocular movements began to improve with methylprednisolone. By the third day of methylprednisolone, VA improved to 20/400. A biopsy of the left orbital apex lesion and a right clival recess lesion was performed. The optic nerve was not biopsied due to positive response to methylprednisolone and avoidance of optic nerve trauma.


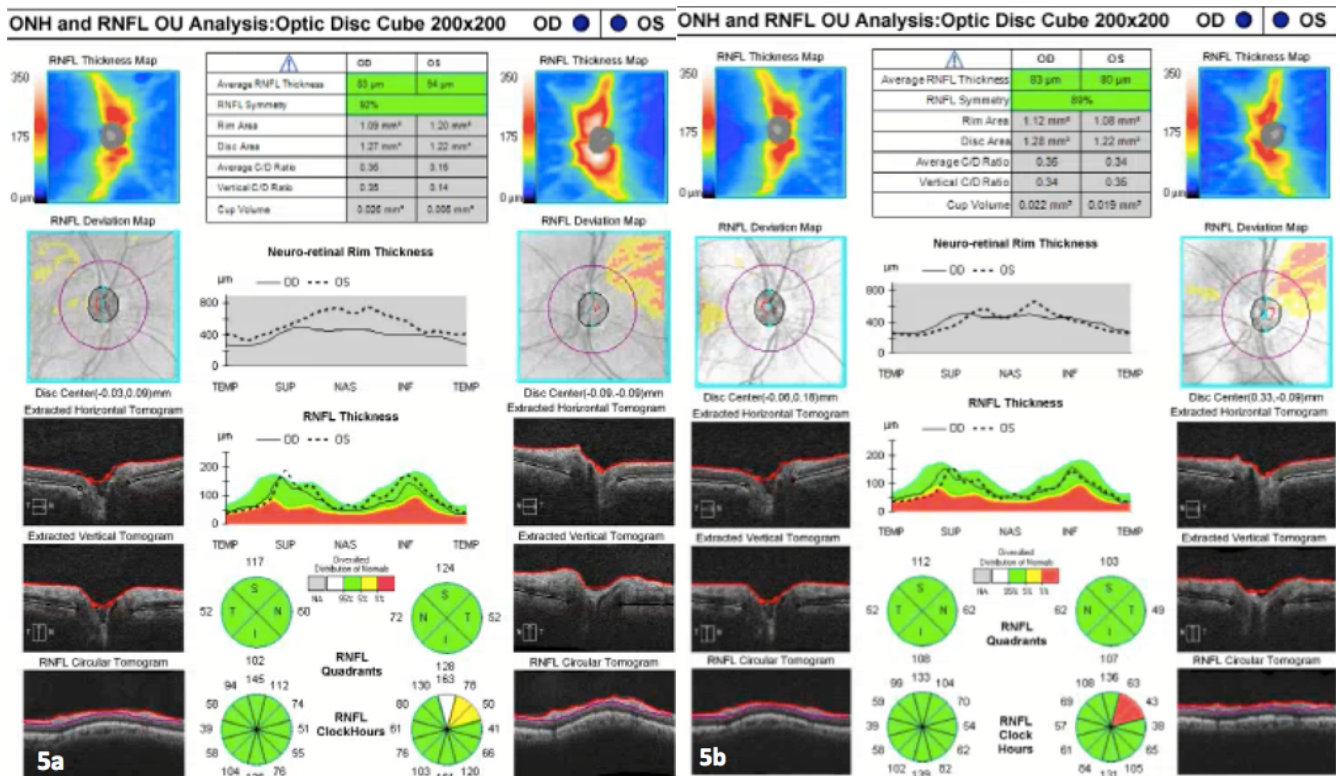


Figure 4.

By the fifth day of methylprednisolone treatment, VA improved to 20/20 in the left eye, extraocular movement had further improved, and color vision had improved with 6/8 color plates being identified. He was discharged from the hospital on daily oral prednisone 80 mg. On a follow-up visit five days later, VA was 20/25 OU, extraocular movement had continued to improve, and color vision was full. First set of Humphrey visual fields were obtained (Figure 4). Optical coherence tomography of the retinal nerve fiber layer (RNFL) was 83 μ m in the right eye and 94 μ m in the left eye (Figure 5A). The ganglion cell inner plexiform layer (GCIPL) average and minimum thicknesses were 74 μ m and 71 μ m, respectively. The GCIPL average and minimum thicknesses were 68 μ m and 61 μ m in the left eye, respectively. Continuation of oral prednisone 80 mg daily for one more week was recommended.

One week later, VA, extraocular movements, and color vision remained stable. The disc edema improved to grade 1 per Frisén scale (Figure 3B). The biopsy showed granulomatous inflammatory changes but no evidence of malignancy or infection. The prednisone was tapered to 60 mg daily with a slow steroid taper planned.



Three weeks later, VA remained 20/25 OU with normal color vision. The RNFL (Figure 5B) and visual fields (Figure 4B) remained stable. Extraocular movements continued to improve to -1 duction in all gazes. On external exam, the proptosis of the left eye had resolved (Figure 2B). Given the various normal lab results, elevated ESR, evidence of inflammation from the biopsy, and response to steroid treatment, the patient was diagnosed with THS.

Discussion

The International Headache Society (IHS) has developed diagnostic criteria for THS.⁶ According to IHS, the following criteria must be met: one or more episodes of unilateral orbital pain persisting for weeks if untreated; paresis of one or more of the third, fourth and/or sixth cranial nerves and/or demonstration of granuloma by MRI or biopsy; paresis coincides with the onset of pain or follows it within two weeks; pain and paresis resolve within 72 hours when treated adequately with corticosteroids; other causes have been excluded by appropriate investigations.⁶

THS is difficult to diagnose largely because it is considered a diagnosis of exclusion. This means that an extensive workup (Table 1) for other conditions such as malignancy, vascular etiologies, and other causes of inflammation must be performed before THS can be diagnosed.⁵ This uncommon disorder can be even more challenging to diagnose when a patient presents with an uncommon symptom. One rare manifestation of THS is visual impairment. One review found that out of 72 cases of THS, only 17 had visual impairment.^{7,8} Additionally, even if the optic nerve is affected, the fundi appear normal in most cases.⁷

Our patient had an uncommon presentation of an uncommon disorder, THS, with vision loss and fundus findings. Despite the unusual appearance of the already rare THS, the systematic diagnostic approach demonstrated in our case led to a timely and accurate diagnosis. Fortunately, his VA and EOMs largely improved after corticosteroid treatment despite the time period from symptom onset to treatment initiation. It is important to perform a thorough workup when THS is suspected because so many other diseases can cause similar or identical presentations. Some other differential diagnoses in this situation can include orbital

pseudotumor, giant cell arteritis, sarcoidosis, granulomatosis with polyangiitis, IgG-4 related disease, or lymphoma. Orbital pseudotumor biopsy often shows nonspecific inflammatory reaction, whereas typically THS is comprised of a granulomatous reaction. Our patient had no definitive signs and symptoms of giant cell arteritis other than headache and elevated ESR. Sarcoidosis, lymphoma, and IgG-4 related diseases were all excluded with lab work. Consideration of THS early, especially in atypical cases involving the optic nerve, is helpful since THS is responsive to corticosteroid treatment. Prompt treatment can decrease the chance of residual symptoms or permanent optic atrophy with GCIPL loss as in this case.⁷ The patient's systemic symptoms of weight loss, nausea leading to decreased appetite, and blood in his urine and stools were not thought to be related to his diagnosis of THS.

Conclusions

The painful ophthalmoplegia observed in THS is due to the mass effect produced in the cavernous sinus or orbital apex. Since many diseases can cause this mass effect, the signs and symptoms of THS are not unique, and this makes THS a diagnosis of exclusion. Rare manifestations of THS such as vision loss, which was present in our case, make the diagnosis of THS even more challenging. Thorough workup, yet prompt treatment, is recommended when THS is suspected.

References

1. Iaconetta G, Stella L, Esposito M, et al. Tolosa-Hunt Syndrome Extending in the Cerebello-Pontine Angle. *Cephalalgia Int J Headache*. 2005;25(9):746-750.
2. Tolosa E. Periarteritic Lesions of the Carotid Siphon with the Clinical Features of a Carotid Infracallosal Aneurysm. *J Neurol Neurosurg Psychiatry*. 1954;17(4):300-302.
3. Hunt WE, Meagher JN, Lefever HE, et al. Painful Ophthalmoplegia: Its Relation to Indolent Inflammation of the Cavernous Sinus. *Neurology*. 1961;11:56-62.
4. Smith JL, Taxdal DS. Painful Ophthalmoplegia. The Tolosa-Hunt Syndrome. *Am J Ophthalmol*. 1966;61(6):1466-1472.
5. Kline LB, Hoyt WF. The Tolosa-Hunt Syndrome. *J Neurol Neurosurg Psychiatry*. 2001;71(5):577-582.
6. Mantia LL, Curone M, Rapoport A, et al. Tolosa-Hunt Syndrome: Critical Literature Review Based on IHS 2004 Criteria. *Cephalalgia*. 2006;26(7):772-781.
7. Andersson BI. Unusual Course of Painful Ophthalmoplegia Report of a Case. *Acta Ophthalmol (Copenh)*. 1980;58(5):841-848.
8. Notter O. The Tolosa-Hunt Syndrome. *Fortschr Neurol Psychiatr Grenzgeb*. 1977;45(8):429-440.

Statement of Ethics

This case report adheres to patient confidentiality and ethical principles in accordance with the guidelines of the Declaration of Helsinki and relevant local regulations. Written consent was obtained from the patient for the publication of this case report.

Conflict of Interest Statement

The authors declare no conflicts of interest related to this topic.

Funding

This work received no funding or grant support.

Authorship

We attest that all authors contributed significantly to the creation of this manuscript, each having fulfilled the criteria as established by the ICMJE.